

Platelet-rich fibrin matrix for improvement of deep nasolabial folds

Anthony P Sclafani, MD, FACS^{1,2}

¹Division of Facial Plastic Surgery, The New York Eye & Ear Infirmary, New York, New York, USA

²Department of Otolaryngology, New York Medical College, Valhalla, New York, USA

Abstract

Background Dermal augmentation continues to grow as an aesthetic facial procedure. Many exogenous filler materials rely on an autologous fibrotic response for volume augmentation.

Aims To evaluate the efficacy of a single injection of autologous platelet-rich fibrin matrix (PRFM) for the correction of deep nasolabial folds (NLFs).

Patients/methods Whole blood was obtained from 15 adults, and an activated autologous PRFM produced using a proprietary system (Selphyl[®]; Aesthetic Factors, Inc., Wayne, NJ, USA) was then injected into the dermis and immediate subdermis below the NLFs. Subjects were photographed before and after treatment; NLFs were rated by the treating physician before and after treatment using the Wrinkle Assessment Scale (WAS) and patients rated their appearance at each post-treatment visit using the Global Aesthetic Improvement Scale. Patients were evaluated at 1, 2, 6, and 12 weeks after treatment.

Results All patients were treated to maximal (no over-) correction, with a mean reduction in WAS score of 2.12 ± 0.56 . At 1 week after treatment, this difference was 0.65 ± 0.68 , but rose to 0.97 ± 0.75 , 1.08 ± 0.59 , and 1.13 ± 0.72 at 2, 6, and 12 weeks after treatment, respectively ($P < 0.001$). No patient noted any fibrosis, irregularity, hardness, restricted movement, or lumpiness.

Conclusions PRFM can provide significant long-term diminution of deep NLFs without the use of foreign materials. PRFM holds significant potential for stimulated dermal augmentation.

Keywords: aesthetic medicine, skin aging, soft tissue augmentation, rhytides, noninvasive

Introduction

Over 4.5 million nonsurgical procedures were performed in the US in 2008 for skin rejuvenation.¹ Volume deficiency in areas of deeper folds, such as the nasolabial folds (NLFs), typically is treated with injectable dermal fillers.² Disadvantages include the transient effects of

temporary, resorbable fillers and foreign body reactions such as encapsulation, granuloma formation, and chronic or delayed infections, in the case of injectable permanent fillers. While some injectable soft tissue fillers currently available (e.g., poly-L-lactic acid) rely on host tissue fibrotic response to produce volume enhancement, they still utilize synthetic, nonbiologic implantable materials. An autologous source for promotion of soft tissue deposition in areas of depletion is desirable.

Human growth factors (GFs) have been extensively investigated, and there are now clinical applications of individual GFs: keratinocyte growth factor (Kevivance[®];

Correspondence: A P Sclafani, MD, FACS, 310 East 14th Street, The New York Eye & Ear Infirmary, New York, NY 10003, USA. E-mail: asclafani@nyee.edu

Accepted for publication October 25, 2009

Biovitrum AB, Stockholm, Sweden) for oral mucositis and platelet-derived growth factor (Regranex[®]; Systage-nix Wound Management, Inc., London, United Kingdom) for nonhealing diabetic wounds. Platelets are an excellent source of human GFs, and they are the primary source of GFs in acute wound healing. Platelet-rich plasma (PRP) preparations have been shown to enhance early healing, in both animal and human models, in a transient way.^{3,4} We have utilized a novel system which produces an autologous platelet-rich fibrin matrix (PRFM), which delivers a more sustained and physiologic platelet growth factor response to augment deep (NLFs) in humans. We propose that, in turn, this procedure constitutes stimulated autologous cell regeneration. We believe this approach can provide a safe and effective correction of deep NLFs and may be applicable in other areas of the face.

Materials and methods

Fifteen healthy adult subjects with moderate to severe NLFs were enrolled in the study. Approximately 9 cc of blood was collected into each of two proprietary collection tubes (Selphyl[®]; Aesthetic Factors, Wayne, NJ, USA) containing a separator gel via standard venipuncture using a 21-gauge butterfly needle. The tubes were then centrifuged at 1100 PRM for 6 min; during the spin the separator gel liquefied to facilitate stratification of blood components and then resolidified when the spin was complete. At this point, the white and red blood cells were separated below the gel, the plasma above the gel and the platelets rested on the upper surface of the gel. After the platelets were resuspended in the supernatant fibrin-rich plasma by inverting the tube, the platelet–fibrin–plasma mix was transferred to a second tube containing calcium chloride. The total time of preparation from venipuncture to injection was approximately 10 min. During this time, the patient was anesthetized with either infraorbital nerve blockade or topical ice. Approximately 4 cc of PRFM was produced per tube; this activated suspension was then injected intradermally or subdermally below the NLFs through 30 and 27 gauge needles, respectively, as needed to achieve the most optimal correction of the NLF with mainly a linear threading technique (although serial puncture injections were performed as needed). All NLFs were treated to full correction only from the alar crease to the level of the oral commissure. Total treatment time (from venipuncture to completion of treatment) was less than 20 min in most cases. Both subjects and the treating physician completed assessments (before and immediately after treatment, and at each follow-up visit), which included a

rating of the NLF severity using the Wrinkle Assessment Score (WAS) and Global Aesthetic Improvement Scale.² Digital photographs were obtained before and immediately after treatment and at each follow-up visit using the Mirror Omnia system (Canfield Imaging Systems, Fairfield, NJ, USA) which incorporates a Canon Power Shot G9 12 megapixel camera and dual xenon flashes at a fixed focal length. Follow-up visits were scheduled at 1, 2, 6, and 12 weeks after treatment.

Results

All subjects completed the study. The average age of subjects was 54.27 ± 12.11 . The average WAS score for NLFs prior to treatment was 3.30 ± 0.47 . Treatment volumes averaged 1.54 ± 0.36 cc per NLF (range 1.0–2.5 cc). Most subjects noted mild bruising which resolved completely within a week of treatment; two patients had trace (<1 cm²) ecchymosis at the 1-week follow-up visit. No patients noted any visible or palpable nodularity at any point in time. No subjects complained of any erythema, soreness, or tenderness for more than the first few hours after treatment. The first five patients were randomly treated with PRFM injected into the dermal plane in one NLF and into the dermal–subdermal junction in the opposite NLF. Results were analyzed by depth of injection (subdermal vs. intradermal), but no significant difference was noted. The remaining 10 patients were then injected bilaterally into both the dermal and subdermal planes as needed, and all NLF results were analyzed cumulatively. All patients noted complete or near-complete improvement in NLFs immediately after treatment, but this correction subsided to varying degrees over the first several days. On average, WAS scores decreased by 2.17 ± 0.56 immediately after treatment; the least improvement was noted at the 1-week visit, although still improved when compared with before treatment. WAS scores decreased an average of 0.65 ± 0.68 at 1 week. Subsequent visits showed WAS score improvements of 0.97 ± 0.75 , 1.08 ± 0.59 , and 1.13 ± 0.72 , at 2, 6, and 12 weeks, respectively ($P < 0.001$ at all time points). All post-treatment WAS scores were significantly improved when compared with pre-treatment; there were no significant differences between the WAS scores at 2, 6, and 12 week follow-up visits (Fig. 1a,b).

Of the 30 NLFs treated, 22 (12 subjects) achieved a change in WAS score of at least 1 point at the 12-week visit. Of those NLFs which ultimately did not achieve at least a 1-point improvement (“nonresponders”), only two of eight achieved at least a 1-point improvement by 2 weeks. Conversely, of 11 NLFs (6 patients) without an

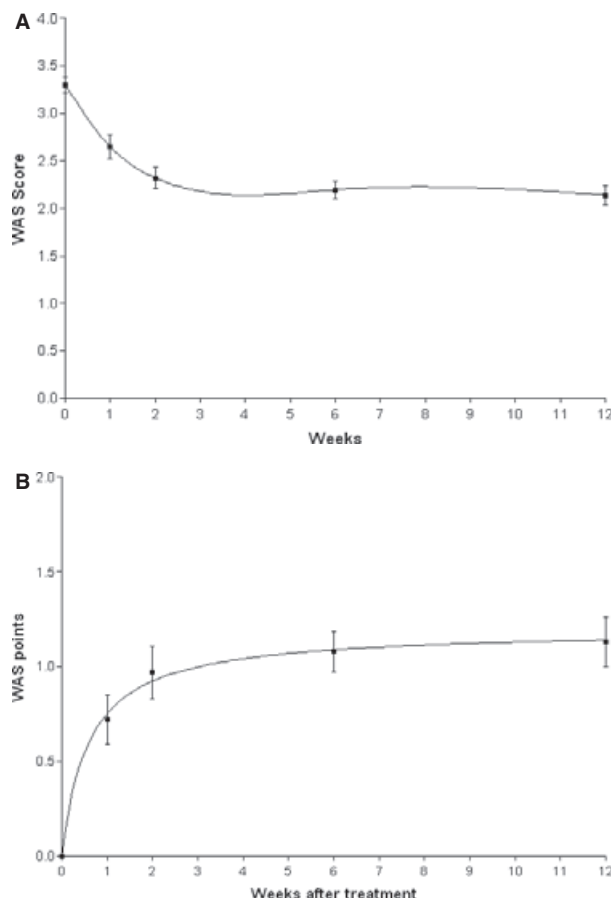


Figure 1 Clinical response after a single injection of PRFM below NLFs. (a) Wrinkle Assessment Scale (WAS) scores as a function of time after injection; (b) change in WAS score over time.

improvement of at least 1 point at 2 weeks, only 3 NLFs (2 patients) achieved at least 1 point improvement at 12 weeks. Two-week response of at least 1 point improvement in the WAS score reliably predicted achievement of at least 1 point improvement at 12 weeks ($P < 0.0001$, Fischer's exact test). The clinical results of responders and nonresponders diverged quickly and significantly (Fig. 2).

The change in WAS score at 12 weeks correlated highly with the subjects' rating of appearance change; a 1-point decrease in WAS score (as rated by the physician) was highly predictive of the subject's assessment of "improved" or "greatly improved" ($P = 0.0475$, Fisher Exact test).

Discussion

Platelet alpha granules contain a number of GFs which are released upon platelet activation. These GFs are

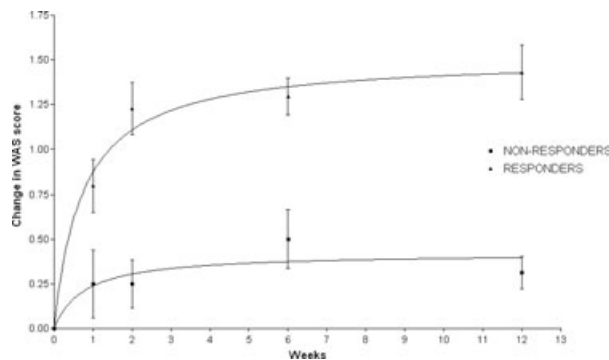


Figure 2 Change in WAS scores after a single injection of PRFM. "Responders" are those NLFs which demonstrated a 1-point or more decrease in WAS score at the 2-week visit.

released in specific ratios which vary over time. Most autologous platelet gel systems commercially available today deliver low concentrations of fibrinogen but high concentrations of platelets, which are activated with exogenous thrombin and calcium; this generally leads to an immediate, massive, and unsustained release of GFs. Some prior studies^{3,4} have shown early but transient histologic and clinical effects associated with such systems, while others have failed to demonstrate any substantial advantage.⁵ However, a more comprehensive and sustained effect may require a more physiologic stimulus.

Kakudo *et al.*⁶ treated human adipose-derived stem cells and dermal fibroblasts with activated or nonactivated platelet-rich (PRP) or platelet-poor plasma (PPP). These workers found an increase in proliferation of stem cells when treated with PRP or PPP activated with calcium and thrombin when compared with nonactivated PRP or PPP, as well as to whole blood; human dermal fibroblasts showed increased proliferation when treated with PRP or PPP, only if activated. Tellingly, both the stem cells and the dermal fibroblasts showed maximal proliferation at 7 days when treated with a 5% PRP, when compared with higher or lower concentrations of PRP; these workers concluded that the appropriate GF concentrations are necessary to maximize effects. Choi *et al.*⁷ also noted that alveolar bone cell proliferation was stimulated by low, but suppressed by high, concentration of PRP.

Platelets in a natural setting will release GFs upon activation in specific concentrations and ratios and continue to synthesize and secrete these factors for up to a week. We believe an amplification of the natural wound response mediated by concentrated platelets and their GFs may produce the most efficacious method of focused autologous collagen expansion when injected

into and below the dermis. We investigated the use of a simple, FDA-cleared class II device to produce a PRFM for *in vivo* dermal augmentation. The PRFM remains in liquid form up to 10 min after contact with calcium chloride, during which time it can be injected easily through a 30-gauge needle. The polymerization of fibrin begins slowly, but accelerates at the higher temperature of the body once injected.

Azzena *et al.*⁸ and Cervelli and Gentile⁹ reported on a single case of a depressed scar and 22 cases of Romberg–Parry disease, respectively, treated with autologous fat mixed with PRFM. PRFM is produced by a proprietary method to produce a fibrinogen–platelet-rich plasma by low speed centrifugation. These platelets have been shown to be highly viable (59% at 7 days after harvesting) and capable of a sustained release of PDGF-BB, VEGF-A, TGF- β , and IGF-1 over 7 days *in vitro*; this has been associated with increased endothelial cell proliferation.^{10,11} A secondary step, a longer centrifugation after the platelet–fibrinogen plasma has been activated with calcium chloride, produces a fibrin product in a loose or compact three-dimensional matrix; platelets are embedded within this matrix. Lucarelli *et al.*¹² noted all serum fibrin and 90% of platelets were located in the matrix after this second step, producing a 60-fold increase in both platelets and fibrin when compared with whole blood. O’Connell *et al.*¹³ noted 65% of venous leg ulcers (which had failed standard therapy) treated with PRFM completely healed within 16 weeks. Interestingly, the divergence of clinical response of those patients who would ultimately heal from those nonresponders was evident by the second and third weeks of treatment.

We were intrigued by the more physiologic approach of PRFM—the high percentage of viable, undergranulated platelets recovered, the three-dimensional fibrin matrix which allowed adherence of platelets at the fibrin nodes, and the sustained release of GFs. Our study is the first trial of PRFM for skin rejuvenation. We initially reasoned that fibroblast stimulation by autologous GFs would stimulate collagen deposition either in the dermis or at the dermal–subdermal junction, and we expected to observe a beneficial effect several weeks after treatment. In the initial follow-up visit 1 week after treatment, we noted the expected partial loss of effect, as the serum injected with the PRFM was resorbed. However, even at the 1-week follow-up visit, there was still some clinical effect, which improved over the next 11 weeks, with an average decrease in the WAS score of 1.13 ($P < 0.001$); the majority of this improvement occurred by week 2 after treatment (Figs. 3, 4). This early response may be because of a

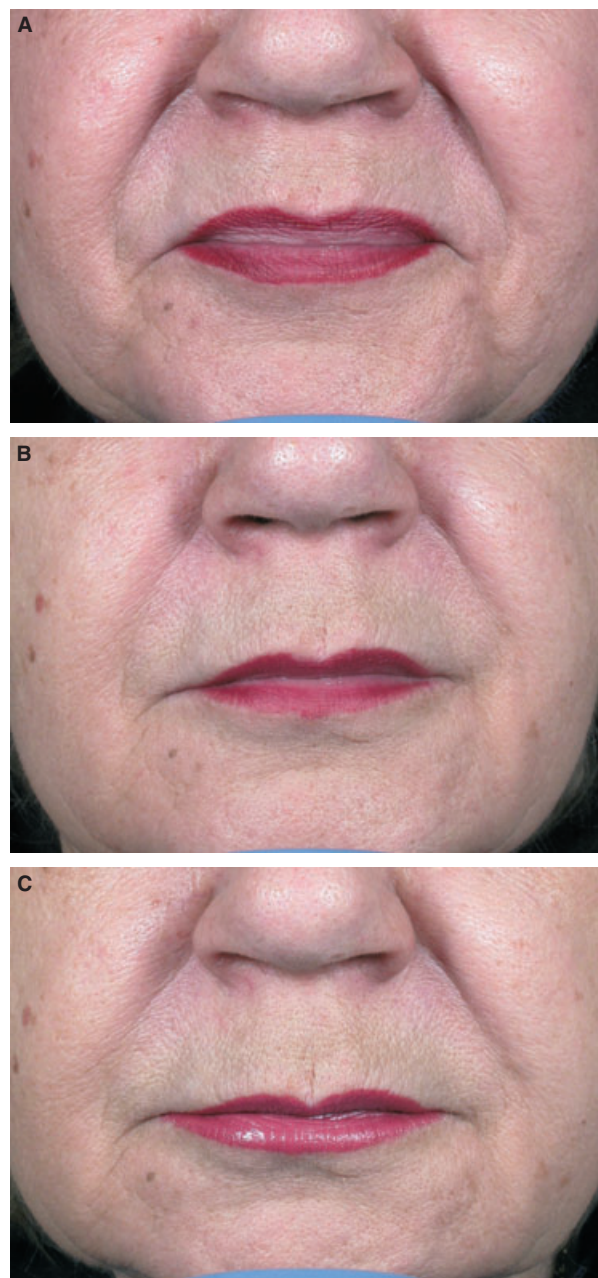


Figure 3 Subject who underwent single treatment of NLFs with PRFM. (a) Pretreatment; (b) 2 weeks after treatment; (c) 12 weeks after treatment.

number of factors: residual serum, transient inflammation, and edema from the treatment, some volume persistence of the fibrin matrix, accelerated collagen, or hyaluronic acid deposition or myofibroblast contraction and/or skin tightening around the NLF. The exact mechanism of action is unclear and is the subject of ongoing studies. Additionally, the subjects in this study

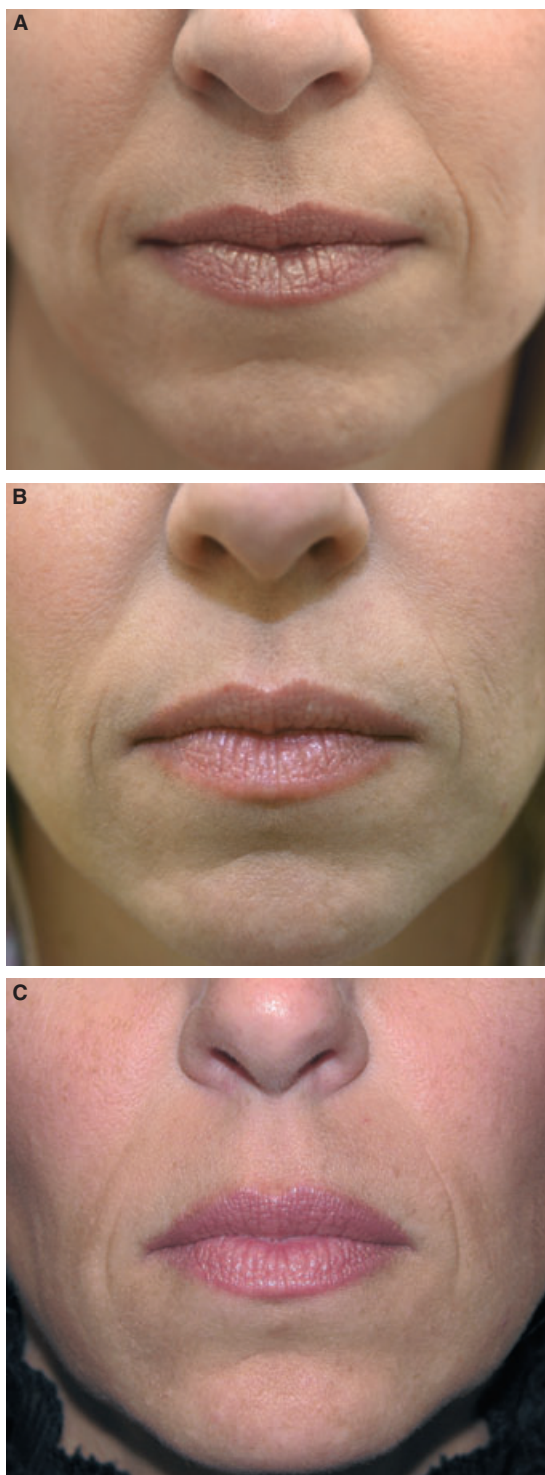

Figure 4 Another subject who underwent single treatment of NLFs with PRFM. (a) Pretreatment; (b) 2 weeks after treatment; (c) 12 weeks after treatment.

are being followed for persistence of effect beyond 12 weeks; no patients have yet complained of loss of effect, with the longest patient follow-up over 9 months after treatment.

A potential disadvantage is the additional time to prepare the PRFM for use, as opposed to commercially available non-autologous filler soft tissue fillers. However, when compared with a dermal stimulator such as PLLA, the preparation time is much shorter. Moreover, the ease with which PRFM can be prepared using the system employed in this study facilitated an efficient process in which blood is drawn first and the patient then anesthetized in the 6–7 min it took to prepare the PRFM. Additionally, there is the need to avoid mishandling and confusing samples if multiple patients' specimen are prepared simultaneously. Given the short time required to process the specimen, it is our policy to have the patient wait in the treatment room while her specimen is individually centrifuged in the same room. The patient visually follows her blood from antecubital fossa to centrifuge to syringe and back into her skin, reinforcing the completely autologous nature of the process. As only one patient's blood is processed at any time, there is no risk of confusing samples between two patients.

Conclusion

Single treatment with autologous PRFM is well tolerated and can produce a significant correction of deep NLFs, without development of excessive fibrosis or the injection of a foreign substance. Unlike other dermal stimulators (e.g., poly-L-lactic acid), PRFM produces its effect rapidly. The system is reproducible and easy to use. Controlled activation of fibrin clotting with calcium chloride initiates fibrinogen cross-linking and obviates bolus degranulation of platelet alpha particles. We are currently expanding our clinical trials to further clarify the specific biological and clinical effects of PRFM.

References

- 1 Cosmetic Surgery National Data Bank Statistics 2008. Published by The American Society for Aesthetic Plastic Surgery; Available at: <http://www.surgery.org/download/2008stats.pdf>; accessed April 3, 2009.
- 2 Lemperle G, Holmes RE, Cohen SR, Lemperle SM. A classification of facial wrinkles. *Plast Reconstr Surg* 2001; **108**: 1735–50.
- 3 Sclafani AP, Romo T, Ukrainsky G, McCormick SA, Litner J, Kevy SV, Jacobson MS. Modulation of wound response and soft tissue ingrowth in synthetic and allogeneic

- implants with platelet concentrate. *Arch Facial Plast Surg* 2005; **7**: 163–9.
- 4 Hom DB, Linzie BM, Huang TC. The healing effects of autologous platelet gel on acute skin wounds. *Arch Facial Plast Surg* 2007; **9**: 174–83.
 - 5 Danielsen P, Jorgensen B, Karlsmark T, Jorgensen LN, Agren MS. Effect of topical autologous platelet-rich fibrin versus no intervention on epithelialization of donor sites and meshed split-thickness skin autografts: a randomized clinical trial. *Plast Reconstr Surg* 2008; **122**: 1431–40.
 - 6 Kakudo N, Minakata T, Mitsui T, Kushida S, Notodihardjo FZ, Kusumoto K. Proliferation-promoting effect of platelet-rich plasma on human adipose-derived stem cells and human dermal fibroblasts. *Plast Reconstr Surg* 2008; **122**: 1352–60.
 - 7 Choi BH, Zhu SJ, Kim BY, Huh JH, Lee SH, Jung JH. Effect of platelet-rich plasma (PRP) concentration on the viability and proliferation of alveolar bone cells: an in vitro study. *Int J Oral Maxillofac Surg* 2005; **34**: 420–4.
 - 8 Azzena B, Mazzoleni F, Abatangelo G, Zavan B, Vindigni V. Autologous platelet-rich plasma as an adipocyte *in vivo* delivery system: case report. *Aesth Plast Surg* 2008; **32**: 155–8.
 - 9 Cervelli V, Gentile P. Use of platelet gel in Romberg syndrome. *Plast Reconstr Surg* 2009; **123**: 22e–23e.
 - 10 Carroll RJ, Arnoczky SP, Graham S, O'Connell SM. Characterization of autologous growth factors in Cascade[®] platelet-rich fibrin matrix (PRFM). *Musculoskelet Transplant Found* 2005, 128-XM 307C5.
 - 11 O'Connell SM, Carroll RJ, Beavis A, Arnoczky. Flow cytometric characterization of Cascade[®] platelet-rich fibrin matrix (PRFM): the impact of exogenous thrombin of platelet concentrates (PC). *Musculoskelet Transplant Found* 2006, 128-2.5M 406TC1.
 - 12 Lucarelli E, Beretta R, Dozza B, Tazzari P, O'Connell S, Santi Spartaco, Ricci F, Squarzoni S, Divieto C, Bontadini A, Tresca G, Oprita E, Donati D. A new bifacial autologous platelet-rich fibrin matrix (PRFM) with enhanced mechanical properties for tissue engineering. *Tissue Eng*, in press.
 - 13 O'Connell S, Impeduglia T, Hessler K, Wang X-J, Carroll R, Dardik H. Autologous platelet-rich fibrin matrix as cell therapy in the healing of chronic lower-extremity ulcers. *Wound Repair Regen* 2008; **16**: 749–56.

Copyright of Journal of Cosmetic Dermatology is the property of Blackwell Publishing Limited and its content may not be copied or emailed to multiple sites or posted to a listserv without the copyright holder's express written permission. However, users may print, download, or email articles for individual use.