

Effects of Local Administration of Vascular Endothelial Growth Factor on Mechanical Characteristics of the Semitendinosus Tendon Graft After Anterior Cruciate Ligament Reconstruction in Sheep

Toshikazu Yoshikawa,^{*†} MD, Harukazu Tohyama,^{*‡} MD, PhD, Taro Katsura,^{*} DVM, PhD, Eiji Kondo,^{*} MD, PhD, Yoshihisa Kotani,[§] MD, PhD, Hideo Matsumoto,[†] MD, PhD, Yoshiaki Toyama,[†] MD, PhD, and Kazunori Yasuda,^{*} MD, PhD

From the ^{}Department of Sports Medicine, Hokkaido University School of Medicine, Sapporo, Japan, the [†]Department of Orthopaedic Surgery, Keio University School of Medicine, Tokyo, Japan, and the [§]Department of Orthopaedic Surgery, Hokkaido University School of Medicine, Sapporo, Japan*

Background: Vascular endothelial growth factor (VEGF) is a potent mediator of angiogenesis.

Hypothesis: An application of VEGF may enhance angiogenesis in the grafted tendon in anterior cruciate ligament (ACL) reconstruction, and the application may affect mechanical characteristics of the ACL graft.

Study Design: Controlled laboratory study.

Methods: Eighteen sheep were divided into groups I and II. In group I, the harvested semitendinosus tendon was soaked in VEGF solution, and the right knee then underwent ACL reconstruction using this tendon. In group II, the right knee underwent identical procedures to those of group I except that the harvested tendon was soaked in phosphate-buffered saline. All animals were sacrificed 12 weeks after ACL reconstruction.

Results: Histologic findings showed that newly formed vessels and infiltrative fibroblasts were more abundant in group I than in group II. The anterior-posterior translation of the knee during an anterior-posterior force of ± 100 N was significantly larger in group I than in group II by 2.58 mm (95% confidence interval, -1.76 mm to 1.76 mm) ($P = .002$). The linear stiffness of the femur-graft-tibia complex in group I was significantly lower than that in group II by 41.5 N/mm (95% confidence interval, -32.2 N/mm to 32.2 N/mm) ($P = .017$).

Conclusion: This study has revealed that VEGF as administered in this study promotes angiogenesis in the ACL graft and significantly reduces the stiffness of the ACL graft with increased knee laxity at 12 weeks after ACL reconstruction.

Clinical Relevance: Exogenous VEGF application for ACL reconstruction can induce an increase in knee laxity and a decrease in the stiffness of the grafted tendon at least temporarily after ACL reconstruction. These potentially negative mechanical effects need to be taken into account when considering clinical use of VEGF.

Keywords: angiogenesis; anterior cruciate ligament; biomechanical properties; vascular endothelial growth factor (VEGF)

[†]Address correspondence to Harukazu Tohyama, MD, PhD, Department of Sports Medicine and Joint Reconstruction Surgery, Hokkaido University School of Medicine, Kita-15 Nishi-7 Kita-ku, Sapporo, 060-8638, Japan (e-mail: tohyama@med.hokudai.ac.jp).

No potential conflict of interest declared.

The natural history of the anterior cruciate ligament (ACL) graft has been documented using histologic, biochemical, and microvascular techniques.^{1,2,3} These studies have shown that the grafted tendon undergoes avascular necrosis, revascularization, cellular proliferation, and matrix remodeling after ACL reconstruction. The canine study by Arnoczky et al² using a microvascular technique has shown that revascularization in the grafted tendon is not complete until 20 weeks after ACL reconstruction, although the

transplanted graft is surrounded by a vascular synovial sheath as early as several weeks postoperatively. With damage to any tissue, cell infiltration from the blood system is thought to be required for tissue healing.⁷ The lack of vascularity within the ACL graft may induce stretch, rupture, or alteration in material properties of the grafted tendon during the postoperative rehabilitation period. Therefore, revascularization in the grafted tendon is required if the graft is to remain a viable substitute for the ACL.

Vascular endothelial growth factor (VEGF) is a potent mediator of angiogenesis that involves activation, migration, and proliferation of endothelial cells in various pathologic conditions.^{8,23} Dodge-Khatami et al⁵ reported that the treatment of free tracheal autografts with VEGF in a rabbit tracheal reconstruction model enhanced healing, as evidenced by accelerated autograft revascularization, reduced submucosal fibrosis and inflammation, and preservation of the normal tracheal architecture. Therefore, there is a high possibility that an application of VEGF to the necrotized tendon graft enhances angiogenesis in the graft. We previously revealed that VEGF significantly promotes angiogenesis in the devitalized ACL with in situ freeze-thaw treatment, but it does not affect the mechanical properties of the in situ frozen-thawed ACL in the rabbit model.¹¹ It is, however, unknown whether an application of VEGF affects the grafted tendon in ACL reconstruction.

Based on the findings of our previous study using an in situ frozen-thawed ACL model, we have hypothesized that an application of VEGF enhances angiogenesis in the grafted tendon in ACL reconstruction and that the application does not affect mechanical characteristics of the ACL graft. The purpose of this study was to test these hypotheses by the sheep ACL reconstruction model using the autogenous semitendinosus tendon graft.

MATERIALS AND METHODS

Experimental Design

Eighteen mature female sheep (Suffolk) weighing 55 to 65 kg were obtained from a licensed laboratory animal dealer. These sheep were divided into 2 groups. In group I ($n = 9$), the semitendinosus tendon harvested from the right leg was soaked in recombinant human VEGF (VEGF₁₆₅; R&D Systems, Minneapolis, Minn) (5 $\mu\text{g}/\text{mL}$) with 10-mL phosphate-buffered saline (PBS) for 15 minutes, and the right knee then underwent ACL reconstruction using this semitendinosus tendon. In group II ($n = 9$), the right knee underwent identical procedures to those of group I except that the harvested tendon was soaked in 10-mL PBS instead of recombinant VEGF with 10-mL PBS. All animals were sacrificed 12 weeks after ACL reconstruction. Animals were used for the following histologic and biomechanical evaluations.

Surgical Procedure

All animal experiments were performed in the Institute of Animal Experimentation of Hokkaido University School of

Medicine under the University Rules and Regulation of Animal Care and Use Committee. Anesthesia was induced intravenously with ketamine hydrochloride. After intubation, anesthesia was maintained with halothane. The right hindlimb was shaved and prepared in the standard sterile fashion.

All surgeries were performed by one of the authors (T.K.) who has 16 years' experience of veterinary surgery, in particular, in the knee joint. After a lateral parapatellar arthrotomy was performed at the right knee, an ACL was excised to identify its insertion sites of the femur and the tibia. The bone tunnels in the femur and the tibia were made at the centers of the insertion sites of the ACL. The tibial tunnel was reamed to 7 mm over a guide pin. For the femoral tunnel, a 4-mm cannulated drill bit was inserted over a guide pin and a 7-mm reamer was inserted for 20 mm from the inside of the knee joint. Through an additional medial skin incision, the insertion of the semitendinosus tendon was exposed and the semitendinosus tendon was separated from the musculotendinous junction of the semitendinosus and was sharply dissected from its insertion of the tibia. In group I, the harvested tendon was immersed in a VEGF solution (5 $\mu\text{g}/\text{mL}$) for 15 minutes. The concentration of VEGF was chosen according to the previous in vivo study which showed that the immersion of tracheal autograft in a 5 $\mu\text{g}/\text{mL}$ VEGF solution improved healing of the tracheal defect in the rabbit model.⁵ After the semitendinosus tendon graft was soaked in a VEGF solution, the graft was doubled over a polyester tape (Endotape, Smith & Nephew, Andover, Mass). The tape was placed through an Endobutton (Smith & Nephew, Andover, Mass) and tied with a 3-throw square knot at a length so that 15 mm of graft was placed within the femoral tunnel. Two No. 3 Ethibond sutures were passed through each end of the tendon grafts in an interdigitating whipstitch fashion. The length and the diameter of the graft were approximately 5 cm and 6 mm, respectively. The graft was tethered to the femur by the Endobutton in the inside-out fashion. After passive flexion-extension of the knee several times, 40 N of tensile load was applied to the sutures connected to the ends of the doubled tendon for 2 minutes at 60° of knee flexion, and then the sutures were fixed to the tibia at the same position under the initial tension of 40 N using a spiked plate (double-spike plate, Smith & Nephew, Andover, Mass). The incision was closed routinely in layers beginning with the deep fascia of the vastus lateralis muscle. In group II, the same procedures as in group I were performed except that the grafted tendon graft was soaked in PBS instead of VEGF solution. Bulky cotton dressing was applied and removed 48 hours after surgery.

To evaluate the mechanical characteristics of the knee at time zero, we performed a pilot study to evaluate the anterior-posterior (A-P) translation of the knees immediately after ACL reconstruction under an A-P force of ± 50 N ($n = 3$ for each group). This pilot study showed that the A-P translation values between the knees immediately after ACL reconstruction in group I were 5.8 ± 0.7 mm, 7.0 ± 0.3 mm, and 5.6 ± 0.9 mm at 30°, 60°, and 90° of flexion, respectively, while those in group II were 5.5 ± 0.9 mm, 6.6 ± 1.8 mm, and 4.8 ± 1.6 mm at 30°, 60°, and 90° of flexion, respectively.

Postoperative Management

Postoperatively, the animals were returned to their cages (2 m × 2 m) and were allowed to put full weight on their limbs without restriction of motion. At day 6 after the surgery, they were allowed to roam freely in a fenced area (approximately 50 m²) and to walk around outdoors for 2 h/d. At 12 weeks after ACL reconstruction, animals were sacrificed by an overdose of potassium chloride after general anesthesia with ketamine hydrochloride. Immediately after the death of the animals, gross assessment of all grafts was performed by 1 investigator (T.Y.) who was unaware of treatment type. In each group, 2 and 6 animals were used for the following histologic and biomechanical evaluations, respectively, since 1 animal was lost for further evaluation in each group because of purulent discharge in the operated knee.

Histologic Examination

Tissue samples were taken from the intra-articular portion of the graft. Samples were fixed in 5% buffered formalin at room temperature for 48 hours. Thereafter, specimens were dehydrated and embedded in paraffin. The 4- μ m thick longitudinal sections were cut and mounted on slides coated with 3% silane (Sigma Chemical, St Louis, Mo). The sections were stained with hematoxylin and eosin (H&E) stain and immunostained with monoclonal anti-human α -smooth muscle actin (Dako, Glostrup, Denmark) for detecting the middle layer of blood vessels. Histologic assessment of the graft was performed by 1 investigator (H.T.), who was unaware of treatment type. For each graft, 3 sections with H&E stain and 2 sections immunostained with α -smooth muscle actin were subjectively evaluated for cellularity and vascularity of the graft, respectively.

Mechanical Evaluation

The knees were harvested, leaving the joint capsule, the collateral ligaments, the menisci, and the cruciate ligaments intact. The specimens were wrapped in saline-soaked gauze and were stored at -32°C until testing. Twelve hours before testing, the knees were thawed at 4°C. The tibial and femoral bone ends were cleaned of all remaining soft tissue and were embedded in aluminum cylinders using polymethylmethacrylate. During all preparations and testing, specimens were kept moist with saline spray. The drawer test was performed in 30°, 60°, and 90° of flexion and neutral rotation with an A-P femoral load application. The knee was mounted to a custom-made adjusting device with 3 degrees of freedom (translations in the anterior-posterior, medial-lateral, and proximal-distal directions) in a materials testing machine (RTC-1210, Orientec, Okabe, Japan).²⁰ To determine neutral knee position, an A-P force of 25 N in both directions was applied. The construct was then adjusted in a way so that the area of linear laxity in the hysteresis curve was parallel to the x-axis. After adjustment, an A-P force of ± 100 N was applied 15 times with a load displacement rate of 50 mm/min. The hysteresis curve was recorded by an X-Y recorder (Model

3023, Yokokawa Engineering, Tokyo, Japan) after the hysteresis curves became constant, and the A-P displacement between ± 100 -N A-P forces was quantified.

After A-P drawer testing, all soft tissue, including the menisci, was removed, leaving only the grafted tendon. In addition, a distal part of the medial femoral condyle was removed so that the entire intra-articular portion of the grafted tendon was visible. The cross-sectional area of the graft was measured at the middle level of the intra-articular portion of the graft by a noncontact optical method with a video dimension analyzer (HTV-C1170, Hamamatsu Photonics, Tokyo, Japan).^{17,21} We evaluated the precision of this cross-sectional area measurement by measuring the cross-sectional area of a stainless steel bar having the circular cross-section with 8.0-mm diameter and found that the 95% confidence interval (CI) of the precision of this method was 0.08 ± 0.33 mm². The femur-graft-tibia (FGT) complex was attached to a set of specially designed grips in the same materials testing machine for A-P drawer testing (RTC-1210, Orientec, Okabe, Japan), so that the tibia was positioned to allow tensile loading aligned with the long axis of the graft at 30° of knee flexion. Before the tensile test, the specimen was preconditioned with a static preload of 5 N for 10 minutes, followed by 10 cycles of loading and unloading with a strain of 0.5% at the crosshead speed of 50 mm/min. Then, the FGT complex underwent tensile testing at the crosshead speed of 50 mm/min until the FGT complex failed.

Statistical Analysis

All data are reported as the mean and standard deviation values. Statistical analyses concerning the cross-sectional area and the structural properties of the FGT complex were made using a 1-way analysis of variance (ANOVA). To compare the A-P translation among the normal control knees and groups I and II, a 2-way ANOVA with repeat measures was performed. When a significant effect was obtained, Fisher protected least significant difference tests were conducted for multiple comparisons. Significance level was set at $P = .05$.

RESULTS

Morphologic Observation

At the death of the animals, we noted swelling of the operated knee with purulent discharge in 1 case for each group. In the other animals, we confirmed that there were no findings indicating infection of the knee joint, for example, swelling or purulent discharge. Therefore, these 2 animals were excluded from further evaluations, and we performed histologic and biomechanical evaluations for 2 and 6 animals in each group, respectively. During the specimen preparation for mechanical testing, we morphologically observed the structures of the knee joint for each specimen. The grafted tendons were enveloped by synovium-like tissues in the intercondylar notch of both groups. These synovium-like tissues were generally thicker and more abundantly vascularized in group I than in

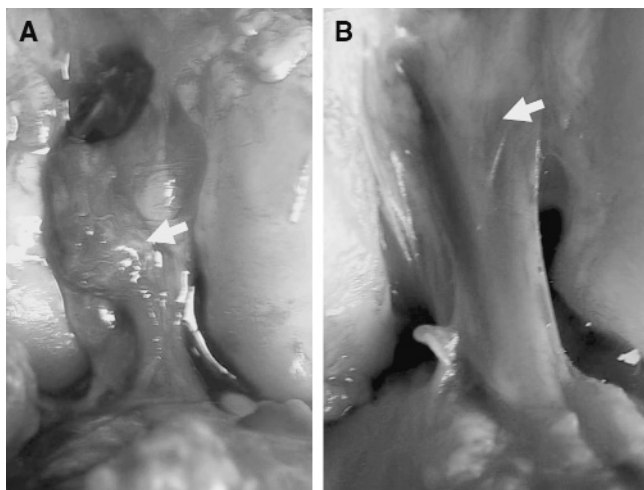


Figure 1. Gross appearances of the grafted tendons 12 weeks after ACL reconstruction in groups I (A, with vascular endothelial growth factor [VEGF] application) and II (B, without VEGF application). The grafted tendons were enveloped by synovium-like tissues (arrows) in the intercondylar notch of both groups. The synovium-like tissues were thicker in group I than in group II.

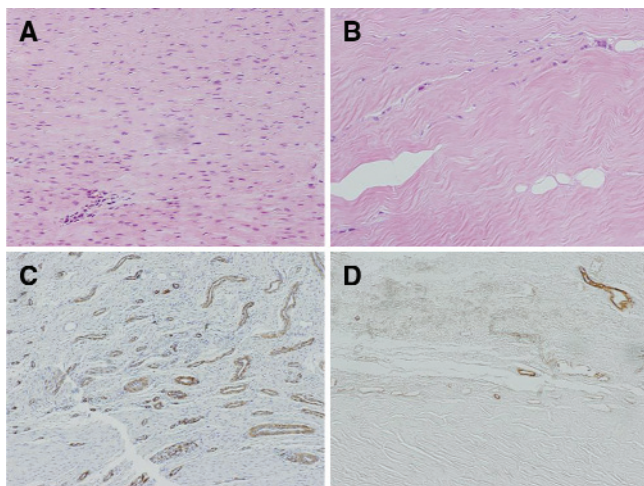


Figure 2. Histologic findings of the grafted tendons 12 weeks after ACL reconstruction with hematoxylin and eosin stain ($\times 100$) (A, group I; B, group II) and actin immunostain ($\times 75$) (C, group I; D, group II) for detecting the middle tunica of blood vessels.

group II (Figure 1). There were no obvious degenerative changes on the articular cartilage and no tear of the menisci in any animal 12 weeks after ACL reconstruction. Concerning the cross-sectional area of the ACL or the graft at 12 weeks after the surgery, we did not detect statistically significant differences among the normal control ($44 \pm 7 \text{ mm}^2$), group I ($62 \pm 31 \text{ mm}^2$), and group II ($55 \pm 16 \text{ mm}^2$) ($P = .566$, power ($1 - \beta$) = 0.125). The mean difference between groups I and II was 7.6 mm^2 (95% CI, -32.3 mm^2 to 32.3 mm^2) ($P = .613$).

Histologically, fibroblasts were uniformly scattered in the core portion of the grafted tendon graft at 12 weeks after

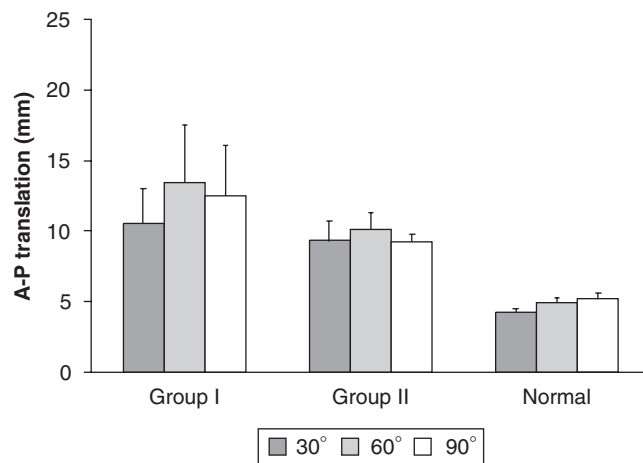


Figure 3. Anterior-posterior (A-P) translation of the tibia relative to the femur between $\pm 100 \text{ N}$ anterior-posterior load at 30° , 60° , and 90° of knee flexion. A 2-way ANOVA with repeat measures showed significant differences among the normal control and groups I and II ($P = .001$), although there was no statistically significant effect of the flexion angle of the knee ($P = .278$) or the interaction effect between grouping and the flexion angle ($P = .760$).

ACL reconstruction in group I (Figure 2A). On the other hand, necrotic portions still existed in the tendon graft at the same period in group II (Figure 2B). In the actin-immunostained sections, a number of vessel formations were frequently found in several superficial portions with disorganized collagen fibers in the tendon graft in group I (Figure 2C). The number of blood vessels in the grafted tendon was obviously greater in group I than in group II (Figures 2 C and D).

Biomechanical Evaluation

Concerning A-P translation of the tibia relative to the femur under $\pm 100 \text{ N}$ of A-P load, a 2-way ANOVA with repeated measures showed significant differences among the normal controls and groups I and II ($P = .001$, $1 - \beta = 1.000$), although there was no statistical effect of the flexion angle of the knee ($P = .278$, $1 - \beta = 0.259$) or the interaction effect between grouping and the flexion angle ($P = .760$, $1 - \beta = 0.145$). The A-P translation of the tibia relative to the femur in group I was significantly larger than that in group II by 2.58 mm (95% CI, -1.76 mm to 1.76 mm) ($P = .002$) (Figure 3). The values in groups I and II were significantly larger than that of the normal control knees (group I, $P = .001$; group II, $P = .001$). The side-to-side differences of A-P translation of the tibia relative to the femur under $\pm 100 \text{ N}$ of A-P load in group I were $6.4 \pm 2.6 \text{ mm}$, $8.6 \pm 3.9 \text{ mm}$, and $7.4 \pm 3.5 \text{ mm}$ at 30° , 60° , and 90° of flexion, respectively, while those in group II were $5.2 \pm 1.5 \text{ mm}$, $5.1 \pm 1.4 \text{ mm}$, and $4.4 \pm 0.4 \text{ mm}$ at 30° , 60° , and 90° of flexion, respectively. A 2-way ANOVA with repeat measures showed significant differences between groups I and II ($P = .005$, $1 - \beta = 1.000$), although there was no statistically significant effect of the flexion angle of the knee ($P = .598$,

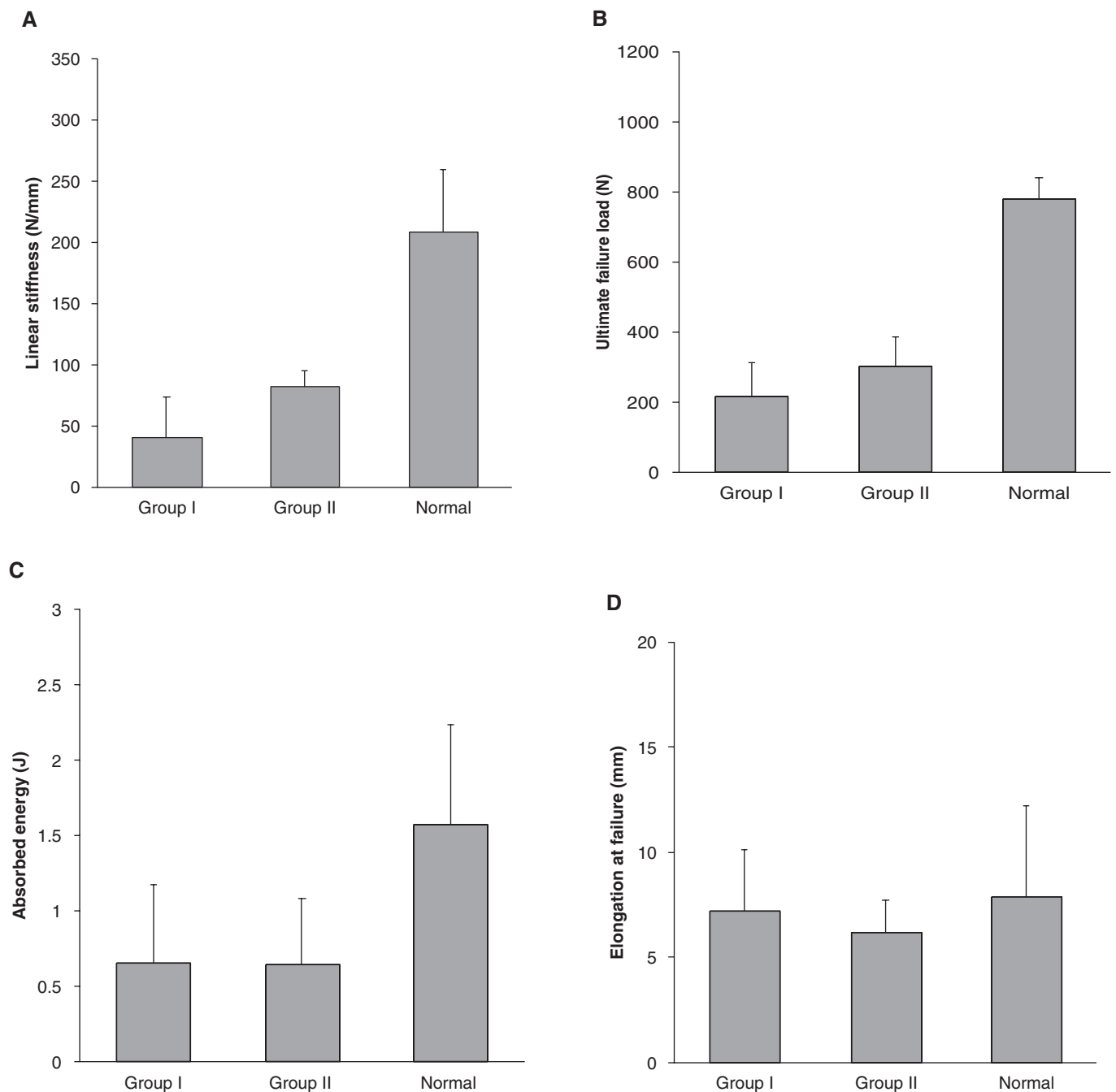


Figure 4. Structural properties of the femur-graft-tibia complex. A, the linear stiffness; B, the ultimate failure load; C, the absorbed energy; D, elongation at failure. A 1-way ANOVA demonstrated significant differences in the linear stiffness, the ultimate failure load, and the energy absorbed at failure among the normal control and groups I and II (the linear stiffness, $P = .001$; the ultimate failure load, $P = .001$; the absorbed energy at failure, $P = .049$), although there were no significant differences in the elongation at the failure ($P = .721$).

$1 - \beta = 0.102$) or the interaction effect between grouping and the flexion angle ($P = .730$, $1 - \beta = 0.155$).

At the failure tests to determine the structural properties of the FGT complex, all grafts failed at the midsubstance portion during tensile testing, while all normal ACL specimens had avulsion fractures at the tibial insertion sites. A 1-way ANOVA demonstrated significant differences in the linear

stiffness, the ultimate failure load, and the energy absorbed at failure among the normal controls and groups I and II (the linear stiffness: $P = .001$, $1 - \beta = 1.000$; the ultimate failure load: $P = .001$, $1 - \beta = 1.000$; the absorbed energy at failure: $P = .049$, $1 - \beta = 0.586$), although there were no significant differences in the elongation at the failure ($P = .721$, $1 - \beta = 0.091$) (Figure 4). The linear stiffness of the FGT complex

in group I was significantly lower than that in group II by 41.5 N/mm (95% CI, -32.2 N/mm to 32.3 N/mm) ($P = .038$) (Figure 4A). The stiffness values of groups I and II were significantly lower than that of the normal complex (group I, $P = .001$; group II, $P = .001$). The average ultimate failure load was lower in group I than in group II by 87 N (95% CI, -135 N to 135 N), although we could not find a significant difference ($P = .154$) (Figure 4B). The ultimate load values of groups I and II were significantly lower than that of the normal complex (group I, $P = .001$; group II, $P = .001$). The energy absorbed at failure of groups I and II was significantly lower than that of the normal complex (group I, $P = .026$; group II, $P = .025$), while there were no significant differences between groups I and II ($P = .977$) (Figure 4C).

DISCUSSION

In this study, we tested the following 2 hypotheses. The first hypothesis was that soaking the hamstring tendon graft in a VEGF solution stimulates angiogenesis in the graft after ACL reconstruction; and the second hypothesis was that soaking the graft in a VEGF solution does not affect the mechanical characteristics of the graft after ACL reconstruction. The gross appearance of the grafts in the present study showed that soaking the graft in the VEGF solution promoted a remarkable increase of synovial tissue with hypervascularity around the graft 12 weeks after ACL reconstruction, and our histologic observation indicated that soaking the graft in the VEGF solution stimulated angiogenesis and cellular infiltration in the tendon grafted at the same period. Therefore, the present study suggested that the first hypothesis is true. On the other hand, our biomechanical evaluation showed that the linear stiffness of the FGT complex soaked in the VEGF solution was significantly lower than in the complex soaked in PBS solution at 12 weeks after ACL reconstruction, although we could not show the statistical difference in the ultimate failure load between the grafts after soaking in the VEGF solution and PBS. In addition, the A-P translation of the knee in group I was significantly larger than that in group II. Therefore, the present study denied the second hypothesis, showing that soaking the graft in the VEGF solution increased the knee laxity and decreased the graft stiffness, at least temporarily, after ACL reconstruction.

There are several limitations in the present study. The first limitation is that we evaluated the semitendinosus tendon graft only 12 weeks after ACL reconstruction. Therefore, it remains unknown if the adverse effect of VEGF administration on mechanical strength of an ACL graft at 12 weeks diminishes over time or not. A further long-term study should be conducted to clarify if the adverse effect of VEGF administration on mechanical strength of an ACL graft is temporal.

Second, we used only a single concentration of VEGF solution to apply VEGF to the tendon graft in the present study. Dodge-Khatami et al⁵ reported that an excised portion of trachea was soaked in 5 $\mu\text{g}/\text{mL}$ VEGF solution for 15 minutes before being reimplanted in the resultant tracheal

opening in a rabbit model of tracheal reconstruction and that this topical treatment of free tracheal autografts with VEGF enhanced healing, as evidenced by accelerated autograft revascularization and reduced submucosal fibrosis and inflammation and caused preservation of the normal tracheal architecture. In the present study, we soaked the tendon graft in VEGF solution in the same condition as the study of Dodge-Khatami et al,⁵ 5 $\mu\text{g}/\text{mL}$ VEGF solution for 15 minutes before ACL reconstruction. We found that tendon autografts with VEGF-enhanced revascularization had a decrease in the stiffness 12 weeks after implantation. However, we cannot refer these findings of the present study to VEGF treatment of tendon autografts with different concentrations of VEGF solution or different soaking times. We need to examine the dose-dependent effects of the mechanical characteristics of the ACL graft.

The third limitation is that we did not measure changes in the VEGF concentration in the ACL graft after its implantation. Concerning the diffusion of VEGF in the tissue, Dodge-Khatami et al⁵ immunohistologically examined VEGF localization in the tracheal specimens soaked in different concentrations of VEGF solution—2, 5, and 10 $\mu\text{g}/\text{mL}$ —and for different soaking durations—1, 5, 15, 30, and 45 minutes. They found that intense staining in the subepithelial layer was similarly achieved with 5 mg/mL at 30 minutes of exposure or longer and with 10 mg/mL at 15 minutes or longer. They also found that at the lower concentration of 2 mg/mL , no detectable staining was noted until 30 minutes and then only lightly in the superficial epithelial layer. The diffusion of VEGF into the tendon, one of the densest collagenous connective tissues, is likely slower than that of these tracheal specimens. Therefore, we assume that the concentration of VEGF solution was too low to achieve the equilibrium state of the VEGF diffusion in the tendon graft within 15 minutes. This may be one of the reasons that the group with VEGF, group I, had large standard deviations in mechanical parameters. However, we clearly found that even this concentration of VEGF significantly affected some of the mechanical parameters of the tendon graft with the enhancement of angiogenesis surrounding the graft.

The fourth limitation is the difficulty of ACL reconstruction in sheep knee joints. Different surgical results might induce some errors in histologic or biomechanical evaluations. In the present study, a single veterinary surgeon with 16 years' experience of veterinary surgery performed ACL reconstruction surgeries. The small deviation of the A-P translation in the control group, group II, reflects high repeatability of the surgeries in the present study. On the other hand, the deviation of the A-P translation in group I was larger than that in group II. We speculate that the difference in biological responsiveness to VEGF among the animals might induce the large standard deviation of A-P translation in group I compared with that in group II.

The fifth limitation of the present study is that our histologic assessment was subjective. However, gross assessment of the grafts showed that all 8 grafts with VEGF application were enveloped by thick synovium-like tissues with hypervascularity, while all grafts without VEGF application were enveloped by thin synovium-like tissues

without hypervascularity. Therefore, we believe these subjective macrofindings and microfindings of the graft suggest that soaking the hamstring graft in VEGF solution stimulates angiogenesis in the graft after ACL reconstruction.

The sixth limitation of the present study is the low number of specimens for histologic examination. Concerning the effect of local administration of VEGF on the vascularity in the ACL graft, we previously reported that local administration of the VEGF enhances the vascularity in the *in situ* frozen-thawed rabbit ACL, the ideal ACL reconstruction model, at 3, 6, and 12 weeks after surgery, by quantitative assessment of vascularity with an acceptable number of the experimental animals.¹¹ In the present study, we only confirmed the angiogenic effect of VEGF application on the graft after sheep ACL reconstruction using subjective assessment because we have already proved the angiogenic effect of VEGF application on the ACL after necrosis using an alternative model with rabbits. On the other hand, our previous rabbit study failed to find significant effects of VEGF on mechanical properties of the rabbit ACL after the freeze-thaw treatment. Therefore, we attempted to determine the effect of VEGF application on the graft using the sheep ACL reconstruction model. In spite of these limitations, however, we believe that the present study has provided useful information concerning the basic science of ACL reconstruction.

Vascular endothelial growth factor stimulates endothelial cells to migrate, proliferate, and form tubes *in vitro*.^{8,10,23} *In vivo* VEGF also functions as an endogenous stimulator of both angiogenesis and increased vascular permeability.^{4,5,6,14,15} We previously investigated the effects of VEGF administration on angiogenesis in the rabbit ACL after the *in situ* freeze-thaw treatment,¹¹ even though devitalizes the ACL *in situ* as a model of an ideal ACL graft. In this previous study, we found that the local administration of VEGF significantly stimulated angiogenesis in the ACL after necrosis. The histologic findings of the present study were consistent with our previous study using the *in situ* frozen-thawed ACL model,¹¹ even though we did not attempt to quantitatively assess angiogenesis in the ACL graft in the present study due to small sample size, 2 animals for each group.

Concerning the measurement of A-P translation, we did not allow all rotation motions of the knee during testing. The design of the device that we used for A-P translation measurement is based on that reported by Sullivan et al.¹⁹ In fact, it is possible to measure A-P translation in 5 degrees of freedom using this device. Actually, we adjusted the knee specimens at the setting zero-point position at each flexion angle in 5 degrees of freedom and then constrained all rotations of the knee specimens during A-P loading. We constrained all rotations of the knee specimens during testing for the following reason: If we allow the rotational motions during loading, we cannot apply load to the tibia constantly in the anterior direction relative to the tibia because the anterior-posterior axis changes depending on the rotational motions of the tibia, as described in the joint coordinate system by Grood and Suntay.⁹ However, this condition is dissimilar to the clinical situation of instrumented measurement of A-P translation. During the instrumented measurement of A-P translation in clinical practice, the load to the lower leg is usually applied in the anterior direction relative to the tibia.

We do not know exactly why our VEGF application reduced the stiffness of the grafted tendon after ACL reconstruction. Shrive et al¹⁸ described in the medial collateral ligament injury model in the rabbit that the area of newly formed vessels, infiltrative cells, and disorderly arranged collagen fibers in the scar tissue was inversely correlated with mechanical strength of the scar tissue and that a number of newly formed vessels and infiltrative cells might act as “flaws” and enhance the deterioration of the mechanical property of the grafted tendon. Therefore, a number of newly formed vessels and infiltrative cells, which VEGF administration induced in the ACL graft, might deteriorate mechanical properties of the ACL graft as soft tissue flaws. In addition, it was reported that VEGF promotes matrix metalloproteinases (MMPs) production by some types of cells.^{8,13,16,23} Therefore, VEGF-induced MMPs directly might digest the matrix of the graft.

Biomechanical findings of the present study in the sheep ACL reconstruction model were different from those of our previous study in the rabbit *in situ* frozen-thawed ACL model,¹¹ even though both of these studies indicated recombinant VEGF application stimulated angiogenesis in the ACL graft or the ACL after necrosis. That is, the adverse effects of VEGF on mechanical characteristics were greater in the present study than in the rabbit *in situ* frozen-thawed ACL. There were several possible reasons for this difference. The first possibility was that biological differences between the free tendon graft model and the *in situ* frozen-thawed ACL model induced a different effect on the mechanical characteristics of the ACL graft. The *in situ* frozen-thawed ACL model did not make any bone tunnels. Therefore, the inflammation in the knee joint was considered to be extremely severe in the ACL reconstruction model with a free tendon graft compared with the *in situ* frozen-thawed ACL model. The inflammation in the knee joint might enhance the biological adverse effects of VEGF on mechanical characteristics of the ACL graft. In addition, there might be some contribution from bone marrow-derived cells to the adverse effects of VEGF on mechanical characteristics of the ACL graft. The second possibility was the difference in the method for recombinant VEGF application between these studies. In our previous rabbit *in situ* frozen-thawed ACL study, we applied recombinant VEGF to the ACL via a single injection to the knee joint, while in the present free graft study, we soaked the graft in the VEGF solution for 15 minutes. The soaking in the VEGF solution might be more effective than a single intra-articular injection of the VEGF for the tissue. The third possibility was the adverse effect of VEGF on the healing in the bone tunnel. The *in situ* frozen-thawed model cannot evaluate the graft healing in the bone tunnels. In the present study, we biomechanically evaluated the FGT complex. Therefore, the VEGF might mainly deteriorate mechanical characteristics of the graft-bone interfaces rather than the graft substance. This third possibility was, however, unlikely because all grafted tendons failed at mid-substances of the ACL graft 12 weeks after the surgery during failure tensile testing. Although we do not know an exact reason for the difference in the adverse effects of VEGF on the ACL graft, we consider that clinical ACL reconstruction cases are more similar to the present sheep reconstruction model than the rabbit *in situ* frozen-thawed ACL model.

As to clinical relevance, VEGF is widely used for patients with extensive tissue ischemia in whom primary vascular reconstruction procedures are not feasible or previously failed in clinical trials.¹² Early clinical data provide evidence that the VEGF application can achieve beneficial angiogenesis with minimal side effects. The present study implies that an application of the recombinant VEGF therapy can supposedly enhance revascularization in the graft as well as cellular infiltration after ACL reconstruction. On the other hand, the present biomechanical results have indicated that exogenous VEGF application decreases the stiffness of the grafted tendon at least temporarily after ACL reconstruction. Therefore, if we intend to apply exogenous VEGF as a treatment to accelerate angiogenesis and cellular infiltration in the tendon graft for ACL reconstruction, we should take into account this adverse effect of exogenous VEGF application on the mechanical characteristics of the grafted tendon.

REFERENCES

- Amiel D, Kleiner JB, Akeson WH. The natural history of the anterior cruciate ligament autograft of patellar tendon origin. *Am J Sports Med.* 1986;14:449-462.
- Arnoczky SP, Tarvin GB, Marshall JL. Anterior cruciate ligament replacement using patellar tendon: an evaluation of graft revascularization in the dog. *J Bone Joint Surg Am.* 1982;64:217-224.
- Clancy WG Jr, Narechania RG, Rosenberg TD, Gmeiner JG, Wisniewski DD, Lange TA. Anterior and posterior cruciate ligament reconstruction in rhesus monkeys. *J Bone Joint Surg Am.* 1981;63:1270-1284.
- Corral CJ, Siddiqui A, Wu L, Farrell CL, Lyons D, Mustoe TA. Vascular endothelial growth factor is more important than basic fibroblastic growth factor during ischemic wound healing. *Arch Surg.* 1999;134:200-205.
- Dodge-Khatami A, Backer CL, Holinger LD, Mavroudis C, Cook KE, Crawford SE. Healing of a free tracheal autograft is enhanced by topical vascular endothelial growth factor in an experimental rabbit model. *J Thorac Cardiovasc Surg.* 2001;122:554-561.
- Dodge-Khatami A, Niessen HW, Baidoshvili A, et al. Topical vascular endothelial growth factor in rabbit tracheal surgery: comparative effect on healing using various reconstruction materials and intraluminal stents. *Eur J Cardiothorac Surg.* 2003;23(1):6-14.
- Fenwick SA, Hazleman BL, Riley GP. The vasculature and its role in the damaged and healing tendon. *Arthritis Res.* 2002;4(4):252-260.
- Ferrara N, Davis-Smyth T. The biology of vascular endothelial growth factor. *Endocr Rev.* 1997;18:4-25.
- Grood ES, Suntay WJ. A joint coordinate system for the clinical description of three-dimensional motions: application to the knee. *J Biomech Eng.* 1983;105:136-144.
- Hippenstiel S, Krull M, Ikemann A, Risau W, Clauss M, Suttrop N. VEGF induces hyperpermeability by a direct action on endothelial cells. *Am J Physiol.* 1998;274:678-684.
- Ju YJ, Tohyama H, Kondo E, et al. Effects of local administration of vascular endothelial growth factor on properties of the in situ frozen-thawed anterior cruciate ligament in rabbits. *Am J Sports Med.* 2006;34:84-91.
- Kusumanto YH, Hospers GA, Mulder NH, Tio RA. Therapeutic angiogenesis with vascular endothelial growth factor in peripheral and coronary artery disease: a review. *Int J Cardiovasc Intervent.* 2003;5:27-34.
- Munaut C, Noel A, Hougrand O, Foidart JM, Boniver J, Deprez M. Vascular endothelial growth factor expression correlates with matrix metalloproteinases MT1-MMP, MMP-2 and MMP-9 in human glioblastomas. *Int J Cancer.* 2003;106:848-855.
- Nicosia RF, Lin YJ, Hazelton D, Qian X. Endogenous regulation of angiogenesis in the rat aorta model. Role of vascular endothelial growth factor. *Am J Pathol.* 1997;151:1379-1386.
- Nissen NN, Pulverini PJ, Koch AE, Volin MV, Gamelli RL, DiPietro LA. Vascular endothelial growth factor mediates angiogenic activity during the proliferative phase of wound healing. *Am J Pathol.* 1998;152:1445-1452.
- Pufe T, Harde V, Petersen W, Goldring MB, Tillmann B, Mentlein R. Vascular endothelial growth factor (VEGF) induces matrix metalloproteinase expression in immortalized chondrocytes. *J Pathol.* 2004;202:367-374.
- Sakai T, Yasuda K, Tohyama H, et al. Effects of combined administration of transforming growth factor-beta 1 and epidermal growth factor on properties of the in situ frozen anterior cruciate ligament in rabbits. *J Orthop Res.* 2002;20:1345-1351.
- Shrive N, Chimich D, Marchuk L, Wilson J, Brant R, Frank C. Soft-tissue "flaws" are associated with the material properties of the healing rabbit medial collateral ligament. *J Orthop Res.* 1995;13:923-929.
- Sullivan D, Levy IM, Sheskiev S, Torzilli PA, Warren RF. Medial restraints to anterior-posterior motion of the knee. *J Bone Joint Surg Am.* 1984;66:930-936.
- Tohyama H, Beynon BD, Johnson RJ, Renstrom PA, Arms SW. The effect of anterior cruciate ligament graft elongation at the time of implantation on the biomechanical behavior of the graft and knee. *Am J Sports Med.* 1996;24:608-614.
- Yamamoto E, Hayashi K, Yamamoto N. Mechanical properties of collagen fascicles from rabbit patellar tendons. *J Biomech Eng [Tr-ASME].* 1994;121:124-131.
- Yoshikawa T, Tohyama H, Enomoto H, et al. Temporal changes in relationships between fibroblast repopulation, VEGF expression, and angiogenesis in the patellar tendon graft after anterior cruciate ligament reconstruction. *Trans Orthop Res Soc.* 2003;29:236.
- Zachary I. Vascular endothelial growth factor. *Int J Biochem Cell Biol.* 1998;30:1169-1174.