

Autologous Growth Factors Combined with Demineralized Bone Matrix Used as an Alternative to Autograft for the Treatment of Recalcitrant Nonunited Fractures of Long Bones: A Report of Six Cases

J. Tracy Watson, MD, Professor of Orthopaedic Surgery, Wayne State University School of Medicine
and Vice-Chief of Orthopaedic Traumatology, Detroit Receiving Hospital, Detroit, MI.

The incidence of long bone fractures has been estimated to be close to 1.5 million per year in the United States alone.¹ Despite advances in instrumentation and surgical techniques, the frequency of nonunion in patients sustaining traumatic long-bone fractures remains at an unacceptably high level, in some reports occurring in up to 5-13 percent of patients.^{2,3} Although numerous alternative therapies to effect healing of nonunion fractures are available, skeletal fixation with autogenous bone grafting remains the preferred treatment. However, autogenous grafting is associated with several shortcomings and complications, including limited quantities of bone for harvest and donor-site morbidity. This is of particular concern for patients undergoing secondary procedures following failure of previous autografting and for patients who present with lifestyles that would predispose them to a higher risk for donor site complications. These patients present a significant clinical challenge to the orthopaedic surgeon justifying continued efforts to identify effective substitutes for autogenous bone graft.

Demineralized bone matrix (DBM) is frequently used as a bone graft substitute material for osseous repair and reconstruction when autogenous tissue is limited or not indicated or feasible. DBM provides the structural integrity important in reconstruction of larger defects and serves as an osteoinductive and osteoconductive scaffold for ingrowth of bone from defect margins.⁴

DBM has been used alone or applied as a composite graft either with autogenous bone graft (extender) or with autologous bone marrow aspirate, with the aspirate providing a source of osteoprogenitor cells to help enhance osteogenic activity.^{5,6} Recently, several investigators have reported promising results incorporating autologous concentrated platelets with bone graft materials to help stimulate osteogenic activity and promote osseous repair. Platelet granules are known to contain a variety of physiologically active substances that are released during degranulation including locally acting growth factors, such as platelet derived growth factor (PDGF), transforming growth factor-beta (TGF- β ; a specific polypeptide within the broader family of polypeptides that includes bone morphogenetic protein), epidermal growth factor (EGF) and vascular endothelial growth factor (VEGF) among others.⁷⁻⁹ These growth factors are small proteins which serve as signaling agents to cells and affect such critical repair functions as cell migration, proliferation, differentiation and angiogenesis.¹⁰

Due to their effects on bone cell metabolism, growth factors are known to be important for regulating effects for bone remodeling and bone healing. Exogenous application of platelet-associated growth factors has been shown to stimulate proliferation of osteoblasts in cultures, has been demonstrated to stimulate the recruitment and proliferation of osteoblasts in rabbit skull defects; and to augment the healing of tibial fractures in rats in a dose-dependent manner.¹¹⁻¹⁴

More recently, the use of platelet concentrate (PC) to supplement iliac crest autografts has been evaluated in a well-established rabbit posterolateral fusion model.¹⁵ Histologic evaluation of spine motion segments explanted five weeks post-surgery demonstrated a trend toward greater osteoblastic activity, higher histologic score and a more robust active front of mineralization with PC supplementation. In the experimental group implanted with a lesser volume of autograft, there was marked improvement in the biomechanical performance of the graft supplemented with PC as compared to the allograft alone. Clinically, use of graft materials as a means to help stimulate orthopaedic bone grafting applications have been encouraging, with several reports documenting positive results in treatment of mandibular and periodontal osseous defects, alveolar ridge and sinus augmentation and lumbar spinal fusion.¹⁶⁻²¹

This paper describes the author's experience with the use of autologous platelet concentrate in combination with demineralized bone matrix as an alternative to autograft for the treatment of recalcitrant nonunited fractures of long bones in six patients; most of whose fractures had failed to unite following repeated attempts with autogenous bone grafting.

Methods and Surgical Technique

The platelet concentrate was prepared using the Symphony™ PCS (distributed by DePuy, a Johnson & Johnson company, Warsaw, IN) following the manufacturer's instructions. This device provides a simple and automatic process for preparing of platelet concentrate in the operating room (*Figure 1*). With the Symphony Platelet Concentrate System (PCS) system, platelet concentrate can be prepared in less than 15 minutes and requires as little as 55 mL of blood.



Figure 1: Symphony PCS

To maintain a high concentration of platelets (i.e., four times native levels), platelets were resuspended in a plasma volume of 10 mL in the case series described here. Preparation of the PC/DBM composite graft was performed by simultaneous application of the platelet concentrate and a solution of calcified bovine thrombin (1000 U/mL, JMI Pharmaceuticals) to the demineralized cortical powder. The use of PC and thrombin in this manner provides an added benefit as it improves the

handling characteristics of the DBM by consolidating the material into a unitary graft, allowing the material to be shaped or cut into pieces to facilitate placement and packing into the defect site.

The nonunion site was exposed through standard incisions, and all previous fixation hardware was removed when present. The atrophic nonunion site was then fully exposed and all fibrous material removed sharply from the nonunion gap. Utilizing a high speed burr, the nonunion gap was decorticated down to punctate bleeding sites to facilitate vascular ingrowth at the nonunion site. Following mixture of the PC/thrombin with 15 – 20 mL of demineralized bone matrix in the form of demineralized cortical powder, the putty-like material was then packed densely into the defect. The graft was then sealed by spraying a second quantity of PC and thrombin onto the recipient site. This produces a clot-like material over the recipient area maintaining the integrity of the graft material into the defect. Stabilization was then accomplished with addition of site-specific hardware followed by routine closure. Suction drainage was not usually performed to avoid the elution of the gel material from the wound.

Results

A brief review of the patients and **Table 1** summarizes a series of six patients treated with the PC/DBM composite.

Table 1. Patient Data

Patient	Age (yrs.)	Sex	Comorbidities	Bone Involved/ Type of Non-Union	Time from Initial Injury	Previous Treatment(s)	Time to union following PC grafting	Final Result
1	67	M	Cardiac pulmonary, diabetes, + smoking	Femur/ atrophic	16 mos.	IM nails with autograft X2, electrical stimulation	28 weeks	Healed, pain free, weight-bearing
2	66	F	Severe cardiac disease	Femur/ atrophic	28 mos.	Fixation with autograft X2	24 weeks	Healed, pain free, weight-bearing
3	58	F	Severe cardiac disease, insulin-depend, diabetes	Femur/ atrophic	22 mos.	IM nails with autograft	26 weeks	Healed, pain free, weight-bearing
4	82	M	ASO, renal disease	Tibia/ atrophic	15 mos.	Cast	18 weeks	Healed, pain free, weight-bearing
5	68	F	Hx of breast cancer/mastectomy/chemo. and radiation	Humerus/ atrophic	15 mos.	IM nail with additional autograft	25 weeks	Healed, pain free, normal function and range of motion
6	25	M	Refused autograft because of occupational fear	Humerus/ atrophic	14 mos.	Closed IM nailing	10 weeks	Healed, pain free, normal function and range of motion

Patient 1

A 67-year-old male with a three-year history of femoral nonunion presented with atrophic nonunion despite two previous procedures involving intramedullary nailing with iliac autografts and electrical stimulation. The intramedullary nail had broken in situ approximately three months prior to consult. The patient's history was significant for severe cardiomyopathy with restrictive pulmonary disease secondary to a long history of smoking. Because of previous grafting procedures and the patient's numerous medical conditions contraindicating a prolonged operative procedure and/or excessive blood loss, no autograft was utilized. The patient underwent nail removal with grafting using autologous PC with DBM only. Fixation was achieved with a blade plate. Radiographic healing was complete at 28 weeks (*Figures 2a-2d*). At last follow-up, 16 months post-surgery, the patient was pain free and ambulating unassisted and had resumed his limited activities of daily living without difficulties.

Figures 2A through 2D: Radiographic review of Patient 1 preoperative, immediate postoperative and follow-up radiographs.




Figure 2A: Preoperative anteroposterior (A/P) radiograph of right femur showing nonunion and broken intramedullary nail.

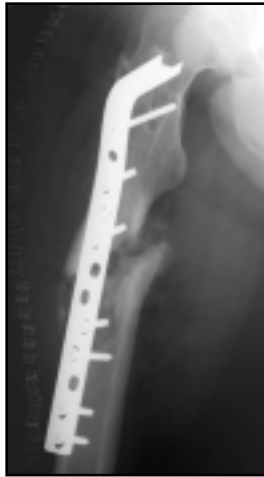
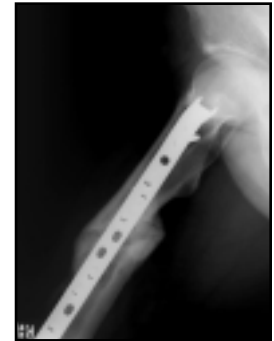
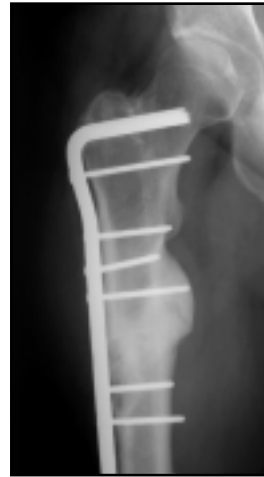
Figure 2B: Immediate postoperative lateral (LAT) radiograph following revision nailing and PC/DBM augmentation.



Figures 2C and 2D: A/P and LAT follow-up radiographs 28 weeks postoperative demonstrating healing.

Patient 2

A 66-year-old female with cardiac disease presented with an atrophic nonunion of the femur despite two previous procedures with fixation and bone autograft. Between the time of her initial referral to our institution and her cardiac clearance for surgery, she sustained a rod fracture two weeks prior to her scheduled surgery date. Because of her severe cardiac disease, this case was done under epidural anesthesia and was accomplished with minimal blood loss. Revision nailing with PC and DBM augmentation was utilized. PC/DBM composite was placed into the defect in an intramedullary fashion by pushing the graft down to the medial defect through the medullary canal entrance portal prior to revision nailing. Femoral canal consolidation was observed within 24 weeks (*Figures 3a-3d*). At 13 months post-surgery, the patient had resumed most of her activities in spite of her cardiac condition, including traveling. She was ambulating with minimal assistive devices (cane) for balance concerns only.

Figures 3A through 3D: Radiographic review of Patient 2, preoperative, immediate postoperative and follow-up radiographs.

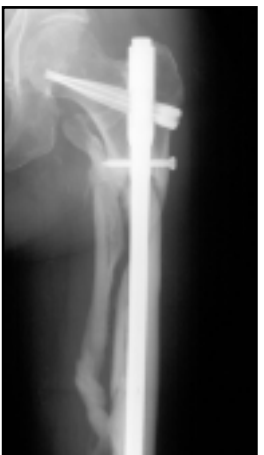

Figure 3A: Preoperative A/P radiographs of left femur and pelvis showing fractured intramedullary rod.

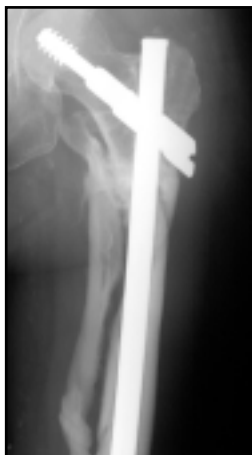
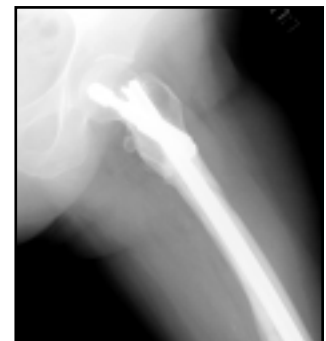
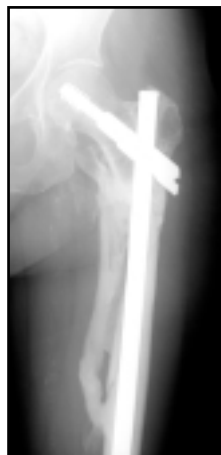Figure 3B: Immediate postoperative A/P radiograph following revision with PC/DBM composite graft.

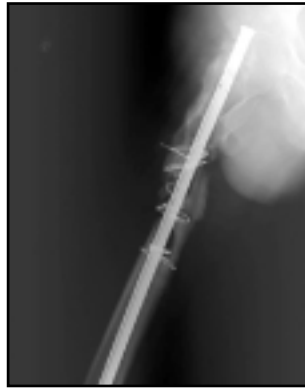
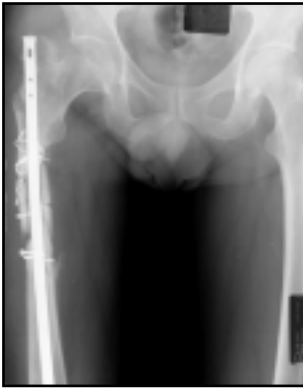

Figures 3C and 3D: A/P and LAT follow-up radiographs taken six months postoperative demonstrating complete femoral canal consolidation.

Patient 3

A 58-year-old female with a previous history of intramedullary nailing three years prior presented with infected, atrophic nonunion of the femur. This patient suffered from severe cardiac disease and insulin-dependent diabetes. The surgical tactic was approached with a staged reconstruction consisting of radical debridement and placement of an antibiotic-impregnated cement nail. Six weeks following this initial procedure, resolution of her infection had been achieved. She then underwent revision open intramedullary nailing with PC and DBM augmentation. Autograft harvest was not considered due to the patient's significant health concerns. Following the second procedure, she achieved complete femoral shaft reconstitution at 26 weeks (*Figures 4a-4g*). At last follow-up, 14 months postoperative, the patient has reported no pain and has resumed her daily activities without noticeable limitation.

Figures 4A through 4G: Radiographic review of Patient 3 preoperative, immediate postoperative and follow-up radiographs.



Figures 4A and 4B: Preoperative A/P and LAT radiographs of pelvis and right femur showing atrophic infected nonunion.

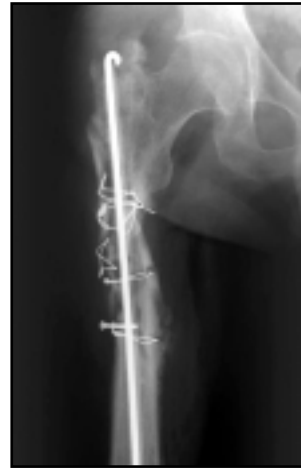
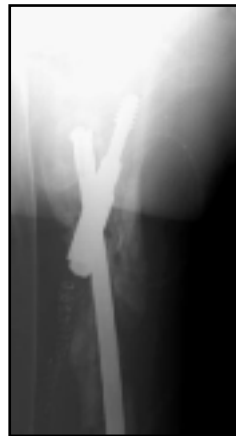
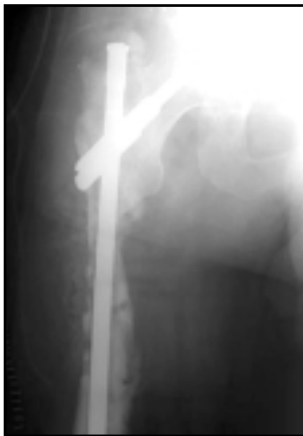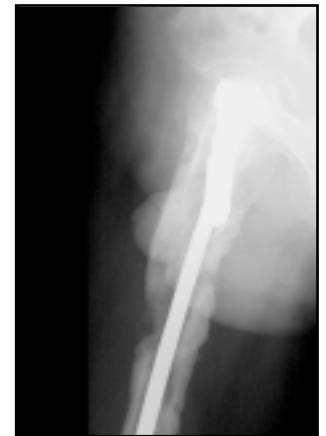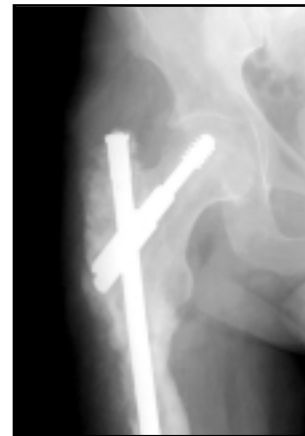Figure 4C: A/P radiograph following revision with antibiotic-impregnated nail.



Figures 4D and 4E: Postoperative A/P and LAT follow-up radiographs immediately following revision IM nailing with PC/DBM grafting.

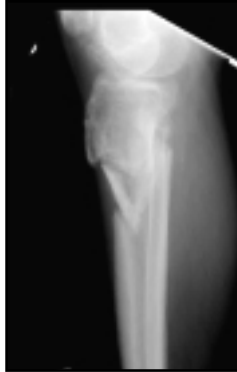
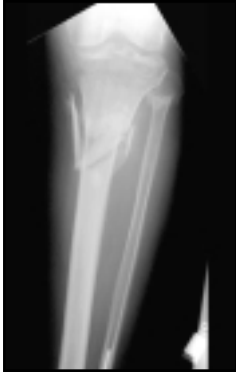
Figures 4F and 4G: Postoperative A/P and LAT follow-up radiographs 22 weeks postoperative demonstrating complete femoral shaft reconstruction.

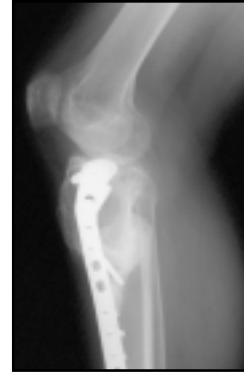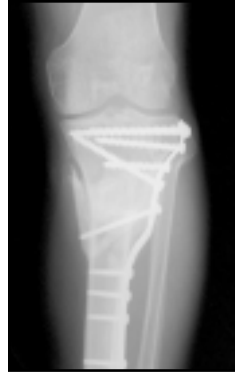Patient 4

An 82-year-old male with a 13-month history of atrophic proximal tibial nonunion presented for treatment. The patient was previously treated with conservative measures, included cast and orthotic management. Co-morbidities included small vessel arterial disease as well as renal compromise. DBM grafting in concert with plate fixation achieved full healing within 18 weeks (*Figures 5a-5d*). One year follow-up documented resumption of activities without pain or assistive devices.

Figures 5A through 5D: Radiographic review of Patient 4 preoperative and postoperative follow-up radiographs.



Figures 5A and 5B: Preoperative A/P and LAT radiographs of tibial nonunion.

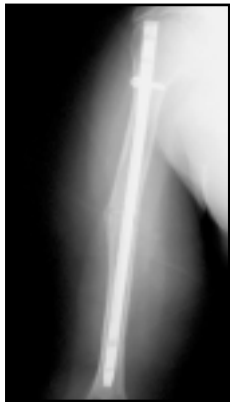
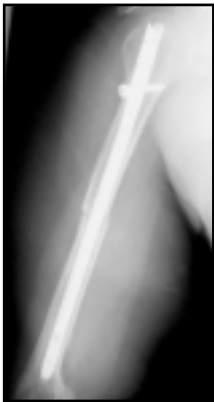
Figures 5C and 5D: Postoperative A/P and LAT radiographs following PC/DBM composite grafting demonstrating healing at 18 weeks.

Patient 5

A 68-year-old female presented with a 15-month history of atrophic humeral nonunion in spite of previous iliac auto-grafting in concert with intramedullary nailing for her midshaft humerus fracture. This patient's medical history was significant for breast cancer with ipsilateral mastectomy. The patient underwent two courses of chemotherapy and one course of radiation therapy. The humeral fracture and subsequent treatment occurred immediately after her chemo and radiation therapy had been completed. She underwent fixation and grafting with PC and DBM. Due to the patient's poor bone quality, she required augmentation of the screw fixation with methylmethacrylate. Complete consolidation at 25 weeks was observed without autografting (*Figures 6a-6f*). Twenty-month follow-up documented resumption of all activities of daily living with no complaints related to her humeral pathology. She was, however, complaining of rotator cuff pain secondary to the previous IM nailing in the arm which had eventually required removal and subsequent revision as was noted above.

Figures 6A through 6F: Radiographic review of Patient 5 preoperative, immediate postoperative and follow-up radiographs.



Figures 6A and 6B: Preoperative A/P and LAT radiographs demonstrating atrophic humeral nonunion.




Figure 6C: Immediate postoperative radiograph following PC/DBM grafting.

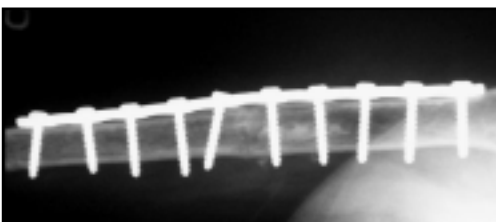
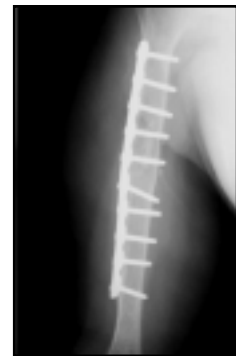
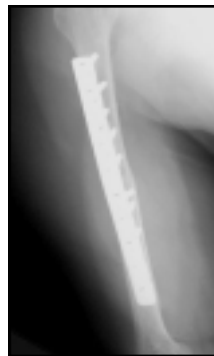

Figure 6D: Six week postoperative radiograph demonstrating onset of graft consolidation.

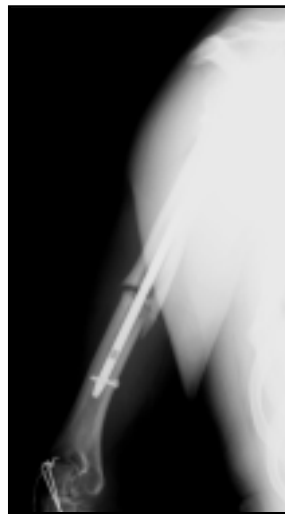
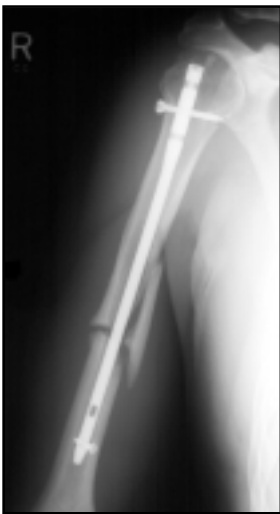

Figures 6E and 6F: Follow-up radiographs demonstrating complete consolidation and healing at 25 weeks.

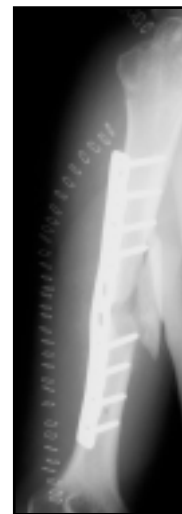
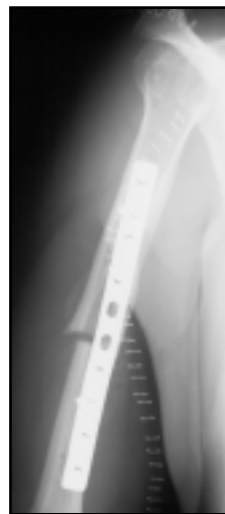Patient 6

A 25-year-old professional motocross racer presented with a 14-month history of atrophic humeral nonunion. The injury was a result of a race-related accident in which the patient sustained a humeral shaft fracture that was initially treated with IM nailing. X-rays noted an atrophic nonunion with distraction of the fracture and no evidence of fracture healing. The patient required revision surgery, but was insistent upon avoiding iliac crest harvesting for occupational reasons. Motocross racers wear protective abdominal binder belts that prevent prolapse of their kidneys due to the continued axial loading of their abdominal contents. The patient was concerned that harvest of autograft from his iliac crests would have precluded the use of the protective belt secondary to pain concerns compromising the patient's career; therefore, it was the patient's preference that his treatment be performed without autograft. He had seen numerous orthopaedic surgeons prior to our consult, however, all wanted to utilize some type of autograft, so, he was referred for grafting using PC augmentation. Revisional plating was performed with PC and DBM and resulted in excellent clinical results and radiographic healing at 10 weeks postoperative (*Figures 7a-7g*). The patient resumed his professional racing career within three-and-a-half months after the surgery, including wearing all of his protective gear. At 18 months post-surgery his X-rays continue to show ongoing callous hypertrophy and complete recanalization across the nonunion site.

Figures 7A through 7G: Radiographic review of Patient 6, preoperative, immediate postoperative and follow-up radiographs.



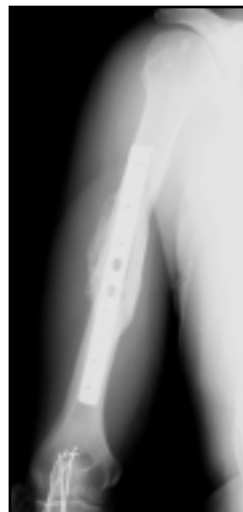
Figures 7A and 7B: Preoperative A/P and LAT radiographs demonstrating atrophic humeral nonunion.



Figures 7C and 7D: Immediate postoperative A/P and LAT radiographs following revision surgery with PC/DBM composite graft.

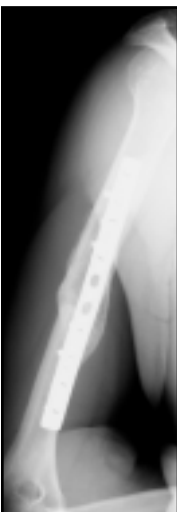
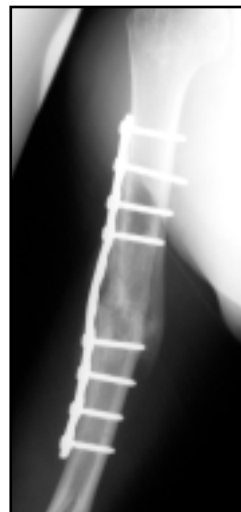
Figure 7E: Oblique 10 week postoperative radiograph demonstrating onset of graft consolidation and healing.



Figures 7F and 7G: 10 week postoperative A/P and LAT follow-up radiographs.

Discussion

The intuitive basis for the use of platelet concentrate (PC) for augmentation of bone graft materials is supported by the practical understanding of the natural physiologic role of platelets in tissue healing and more specifically in bone repair. Fracture healing begins immediately following injury, when growth factors, including TGF- β 1 and PDGF, are released into the fracture hematoma by platelets.²²

These proteins have been demonstrated to exhibit chemotactic effects toward human osteoblasts and are known to have a mitogenic effect on osteoblast precursor cells causing them to multiply and secrete additional growth factors.¹¹⁻¹² Furthermore, the local hematoma provides an osteoconductive matrix, which serves as a scaffold for the bone healing response.

Augmenting the bone graft material with platelet concentrate and bovine thrombin mimics this initial healing response by forming a highly concentrated platelet clot. When the platelet concentrate reacts with thrombin, a fibrin matrix (clot) is formed and the activated platelets release a multitude of growth factors at elevated levels within the local site, due to the increased number of platelets in the concentrate.

The importance of growth factors in bone remodeling and bone healing was established by the pioneering work of Marshall Urist who identified a family of proteins with osteoinductive properties. Since that time, there have been several clinical evaluations of singular human recombinant proteins known to effect bone repair (e.g.,

bone morphogenetic protein -2, rhBMP-2 and Osteogenic Protein -1, also referred to as rhBMP-7), but as yet these products are not FDA approved in the United States for routine orthopaedic use.²⁵⁻²⁶ Additionally, it has been suggested that interactions between the various growth factors, naturally present in the bone cell microenvironment, provide a synergistic effect for bone cell proliferation.²⁶ Lind et al. demonstrated that growth factor combinations resulted in synergistic stimulative effects of the metabolic functions of human osteoblasts.¹² Another study performed by Kasperk et al. evaluating growth factor interactions concluded that TGF- β , IGF-II and FGF modify the activity of other growth factors and cytokines and actually have a synergistic effect in combination.²⁷ The potential advantage of platelets is that these cells provide a physiological combination of growth factors involved in osseous repair.

Conclusion

In this series, the potential benefit of augmenting demineralized bone powder with PC has been demonstrated in that all cases healed without the use of iliac autograft. Furthermore, there were no infections or other complications associated with the use of the PC/DBM composite graft. The use of platelet concentrate significantly improved the handling characteristics of the bone powder, making it easier to fill the defect. Results from this series suggest that the use of platelet concentrate with demineralized bone may provide a feasible bone graft substitute, particularly in cases having failed previous autografting.

REFERENCES

1. Praemer, A., S. Funer and D.P. Rice. Musculoskeletal Conditions in the United States. American Academy of Orthopaedic Surgeons Feb. 1992.
2. Davila, J., A. Malkani and J.M. Paise. "Supracondylar Distal Femoral Nonunions Treated with a Megaprosthesis in Elderly Patients: A Report of Two Cases." *Journal of Orthopaedic Trauma* 2001: 574-578.
3. Corley, F.G., G.K., William, J.C. Pearce, et al. AAOS Instructional Course Lectures. Vol. 39 1990: 277-288.
4. Glowacki, J. "Tissue Response to Bone-Derived Implants." W.B. Saunders Company, Philadelphia, 1992: 84-92.
5. Tiedeman, J.J., K. L. Garvin, T.A. Kile and J.F. Connolly. "The Role of A Composite, Demineralized Bone Matrix and Bone Marrow in the Treatment of Osseous Defects." American Academy of Orthopaedic Surgeons March 1991: 1153-1158.
6. Connolly, J.F. "Injectable Bone Marrow Preparations to Stimulate Osteogenic Repair." *Clinical Orthopaedics and Related Research* No. 313 April 1995: 8-18.
7. Hwang, D.L., L.J. Latus and A. Lev-Ran. "Effects of Platelet-Contained Growth Factors (PDGF, EGF, IGF-1, and TGF- β) on DNA Synthesis in Porcine Aortic Smooth Muscle Cells in Culture." *Experimental Cell Research* 200 1992: 358-360.
8. Piché, J.E. and D. T. Graves. "Study of the Growth Factor Requirements of Human Bone-derived Cells: A Comparison with Human Fibroblasts." *Bone* 1989: 131-138.
9. Ksander, G.A., A. M. Steven, J. Sawamura, et al. "The Effect of Platelet Releasate on Wound Healing in Animal Models." *Journal of the American Academy of Dermatology* 1990: 781-791.
10. Trippel, S.B., R.D. Coutts, T.A. Einhorn, et al. "Growth Factors as Therapeutic Agents." *The Journal of Bone and Joint Surgery* Aug. 1996: 1272-1286.
11. Slater, M. et al. "Involvement of platelets in stimulating osteogenic activity." *Journal of Orthopaedic Res*, 13, 1995: 2-37.
12. Lind, M. "Growth Factor Stimulation of Bone Healing. Effects on Osteoblast, Osteomies and Implants Fixation." *Acta Orthopaedica Scandinavica* Supplementum No. 283, Vol. 69 1998: 1-37.
13. Beck, S.T., E.P. Amento, X. Yvette, et al. "TGF- β Induces Bone Closure of Skull Defects: Temporal Dynamics of Bone Formation in Defects Exposed to rhTGF- β ." *Journal of Bone and Mineral Research* No. 6, Vol. 8 1993: 753-761.
14. Nielsen, H.M., T.T. Andreassen, T. Ledet and H. Oxlund. "Local Injection of TGF- β Increases the Strength of Tibial Fractures in the Rat." *Acta Orthopaedica Scandinavica* 1994: 337-341.
15. Seithi, P. M., J. Miranda, J.N. Grauer, et al. "The Use of Platelet Concentrate in Posterolateral Fusion: Biomechanical and Histological Analysis." International Society for the Study of Lumbar Spine June 2001.
16. Marx, R.F., E. R. Carlson, R.M. Eichstaedt, et al. "Platelet-rich Plasma: Growth Factor Enhancement for Bone Grafts." *Oral and Maxillofacial Surgery* No. 6 Vol. 85 June 1998: 638-646.
17. Whitman, D.H. R. L. Berry and D.M. Green. "Platelet Gel: An Autologous Alternative to Fibrin Glue with Applications in Oral and Maxillofacial Surgery." *Journal of Oral Maxillofacial Surgery* 1997: 1294-1299.
18. Obarrio, J.J., J.L. Araú-Dutari, T.M. Chamberlain and A. Croston. "The Use of Autologous Growth Factors in Periodontal Surgical Therapy: Platelet Gel Biotechnology-Case Reports." *The International Journal of Periodontics & Restorative Dentistry* No. 5, Vol. 20 2000: 487-497.
19. Kassolis, J. D., P. S. Rosen and M. A. Reynolds. "Alveolar Ridge and Sinus Augmentation Utilizing Platelet-Rich Plasma in Combination with Freeze-Dried Bone Allograft: Case Series." *Journal Periodontol* No. 10, Vol. 71 Oct. 2000: 1654-1661.
20. Anitua, E. "Plasma Rich in Growth Factors: Preliminary Results of Use in the Preparation of Future Sites for Implants." *The International Journal of Oral & Maxillofacial Implants* No. 4, Vol. 14 1999: 529-535.
21. Lowery, G.L., S. Kulkarni and A. E. Pennisi "Use of Autologous Growth Factors in Lumbar Spinal Fusion." *Bone* No. 2, Vol. 25 Aug. 1999: 47S-50S.
22. Bolander, M.E. "Regulation of Fracture Repair by Growth Factors." The Society for Experimental Biology and Medicine 1992.
23. Mizuna, K., K. Mineo, T. Tachibana, et al. "The Osteogenic Potential of Fracture Haematoma: Subperiosteal and Intramuscular Transplantation of the Haematoma." *The Journal of Bone and Joint Surgery [Br]* 1990: 822-829.
24. Urist, M.R., R. Granstein, H. Nogami L. Svenson and R. Murphy. "Transmembrane Bone Morphogenesis Across Multiple-Walled Diffusion Chambers: New Evidence for a Diffusible Bone Morphogenetic Property." *Archives of Surgery* Vol. 112 May 1977: 612-619.
25. Orthopedics and Rehabilitation Devices Advisory Panel, Public Meeting. Food and Drug Administration Jan. 2002.
26. Friedlaender, G.E., C. R. Perry, J. D. Cole, et al. "Osteogenic Protein-1) Bone Morphogenetic Protein-7) In the Treatment of Tibial Non unions: A Prospective, Randomized Clinical Trial Comparing RhOP-1 with Fresh Bone Autograft." *The Journal of Bone and Joint Surgery* Supplement 1, Part 2 Vol. 83-A 2001: S1-151-S1-158.
27. Kasperk, C.H. J.E. Wergedal, S. Mohan, et al. "Interactions of Growth Factors Present in Bone Matrix with Bone Cells: Effects on DNA Synthesis and Alkaline Phosphatase." *Growth Factors* 1990: 147-158.

Dr. Watson is a paid consultant for DePuy Orthopaedics, Inc.

CAUTION: Federal Law (USA) restricts these devices to sale by or on the order of a physician.
Consult the package insert for complete product information.
For more information about DePuy products, visit our web site at www.jnjgateway.com.

